高分辨磁共振成像在直肠癌壁外血管侵犯(EMVI)评估中的价值

崔春艳,田　丽,姜　武,李　立
(华南肿瘤学国家重点实验室,中山大学肿瘤防治中心,广东 广州 510060)

摘　要:[目的]探讨高分辨 MRI 在直肠癌壁外血管侵犯(EMVI)评估中的价值。[方法]回顾性分析 109 例经病理证实的直肠癌患者,术前行高分辨 MRI 检查。MRI 评估 EMVI 的情况,并与手术病理对照。[结果]109 例患者中,病理学显示 EMVI 阳性 18 例,EMVI 阴性 91 例;MRI 显示 EMVI 阳性 16 例,EMVI 阴性 93 例, 正确诊断 103 例,MRI 诊断 EMVI 准确率为 94.50%(103/109),过高诊断 2 例,过低诊断 4 例。MRI 与病理学对 EMVI 阳性的诊断一致性良好 (Kappa 值=0.791,P<0.001)。[结论]高分辨 MRI 对直肠癌术前 EMVI 的准确性较好,MRI 能够为直肠癌的个体化治疗方案提供影像学依据。

主题词:MRI;直肠肿瘤;壁外血管侵犯
中图分类号:R735.3+7　**文献标识码**:A　**文章编号**:1671-170X(2019)08-0733-05
doi:10.11735/j.issn.1671-170X.2019.08.B011

Evaluation of Extramural Vascular Invasion in Rectal Cancer with High Resolution MRI

CUI Chun-yan,TIAN Li,JIANG Wu,LI Li
(*State Key Laboratory of Oncology in South China,Sun Yat-Sen University Cancer Center, Guangzhou* 510060,*China*)

Abstract:[Objective] To assess the application of high resolution MRI in evaluation of vascular wall invasion (EMVI) for rectal cancer patients. [Methods] One hundred and nine patients with pathologically confirmed rectal cancer underwent preoperative high-resolution MRI examination. The application of MRI in detection of EMVI was evaluated by comparing with pathological results. [Results] Among 109 patients,pathology showed 18 cases with positive EMVI and 91 cases with negative EMVI;MRI showed positive EMVI in 16 cases,and negative EMVI in 93 cases. The Kappa test showed that MRI was well consistent with pathological results for EMVI(Kappa coefficient=0.791,P<0.001). With pathological finding as a golden standard the diagnostic accuracy of MRI was 94.5%(103/109). Two cases were over-diagnosed and 4 cases was under-diagnosed by MRI. [Conclusion] High-resolution MRI shows a good accuracy in preoperative diagnosis of EMVI for rectal cancer patients.

Subject words:magnetic resonance imaging;rectal cancer;extramural vascular invasion

结直肠癌(colorectal cancer,CRC)是常见的消化系统的恶性肿瘤,结直肠癌 50%~70%发生在直肠[1-2]。直肠癌生存率提高是因为治疗方式的改善, 主要是全直肠系膜切除术 (total mesorectal excision,TME)成为基本术式,同时结合新辅助放化疗的应用,提高了治疗效果[1]。壁外血管侵犯(extramural vascular invasion,EMVI)是直肠癌局部和远处复发以及较差预后的独立危险因素[3-5],EMVI 定义为固有肌层外血管内有恶性细胞的存在[6]。最近,MRI 显示 EMVI 的严重程度发现与无瘤生存期 (disease free survival,DFS)[4] 相关。MRI 已被证明是能表明直肠癌 EMVI 存在的唯一成像方式[7]。目前对 MRI 在直肠癌的术前分期研究中,多侧重于直肠癌 MRI 的术前 T、N 分期,对于直肠癌 EMVI 的研究尚少。因此本研

基金项目:广东省医学科研基金指令性课题项目(C2016072);广东省医学科研基金项目(A2016320)
通信作者:李立,主任医师,教授,博士;中山大学肿瘤防治中心影像科, 广东省广州市越秀区东风东路 651 号(510060);E-mail:lil@sysucc.org.cn
收稿日期:2018-01-27;**修回日期**:2018-05-29

究探讨高分辨 MRI 对直肠癌 EMVI 进行影像学评估价值，为直肠癌的个体化治疗方案提供准确的影像学依据。

1 资料与方法

1.1 临床资料

回顾性分析我院 2014 年 1 月至 2015 年 12 月经病理活检确诊的直肠腺癌患者 109 例，其中男性 63 例，女性 46 例，中位年龄 59 岁(30~81 岁)。所有患者均行术前 MRI 检查，手术前均没有经历放化疗。患者均签署知情同意书。

1.2 MRI 检查方法

仪器设备：采用 Trio Tim 3.0 T MRI 扫描仪(Siemens Medical System，Erlangen，Germany)。扫描的步骤及意义[8-10]：①：患者取仰卧位，MRI 检查先进行定位线扫描。对直肠行矢状位 T2 加权成像(T2 weighted imaging，T2WI)扫描。②：轴位 T2WI。③：行直肠轴位 T1 加权成像 (T1 weighted imaging，T1WI)。④：冠状位 T2WI。⑤：行直肠轴位高分辨 T2WI。此序列是评价 EMVI 的最重要序列。⑥：弥散加权成像(diffusion weighted imaging，DWI)序列，采用单次激发平面回波成像 (single-shot echo-planar imaging，SS-EPI)序列，b 值取 0、800s/mm^2。可以帮助评价肿瘤的 EMVI，但是必须结合高分辨 T2WI。⑦：动态增强序列，以自动高压注射器经手背静脉注射对比剂 Gd-DTPA，注射剂量 0.1 mmol/kg，速率 3 ml/s，行 T1WI 的轴位、冠状和矢状三个方向的扫描。见 Table 1。

1.3 MRI 图像分析

检查结束后将扫描的数据传输至图像存储与传输系统 (Picture Archiving and Communication System，PACS)工作站，影像学资料均由两位高年资腹部影像学诊断医师独立阅片。

壁外血管侵犯(EMVI)被定义为固有肌层外血管内有恶性细胞的存在。直肠周围正常的壁外血管的 MRI 特征是在 T2WI 为匐行性或曲折的线性结构。EMVI 的 MRI 征象是肿瘤的信号存在于血管结构内，血管增宽或者肿瘤膨胀超出血管壁并破坏血管边界[4,6]。具体分型见 Figure 1。

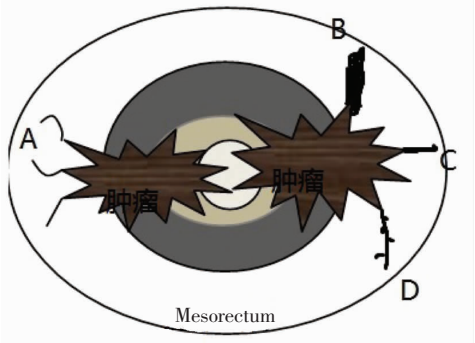

Without EMVI：A，the blood vessels were close to the tumor but there was no tumor signal in the lumen. In suspected EMVI：B，there were tumor signals in the dilated lumen；C，there were tumor signal，but no lumen expansion；D，tumor nodule invasion of the vascular lumen

Figure 1 The diagnostic criteria of MRI rectal EVMI invasion according to the document [11]

本研究中将 EMVI 分为阴性和阳性两组，根据文献[4,6]的 EMVI 分级量表，具体见 Table 2。Grades 0~2 为 EMVI 阴性患者，没有区别；Grade 3~4 对应于 EMVI 阳性的疾病，Grade 3 级 EMVI 描述肿瘤血管没有改变轮廓，可能稍微膨胀，Grade 4 级 EMVI 描述了一个不规则的扩张的血管，意味着血管壁浸润，血管中央见异常信号，血管管壁可能严重膨胀，同时有不规则的轮廓。

1.4 手术病理方法

所有患者外科标本经病理学检查，将标本置于 10%中性福尔马林液固定 24h，大体标本取材时，在肠壁浸润最深处。石蜡包埋常规切片取材，HE 染色，评估肿瘤的壁外血管是否受侵。HE 染色判定脉管浸润的标准为：血管或淋巴管管腔样结构内发现癌栓，管腔与癌栓相连，或肿瘤细胞直接包绕、侵犯血管或淋巴管壁，参照文献[12]描述的方法，根据免疫组化 CD34 和 D2~40 状态判定脉管浸

Table 1 Scanning parameters of MRI

Index	Sagittal TSE/T2	Axial TSE/T2	Axial SE/T1	Coronal TSE /T2	Axial high resolution TSE/T2	DWI
TR/TE(ms)	3200/83	3200/83	666/10	4000/102	3200/83	4000/70
Section thickness/interval	4/1mm	5/1mm	5/1mm	3/1mm	3/0mm	5/1mm
FOV	26cm	26cm	26cm	26cm	16~19cm	26cm
Matrix	256×192	256×256	320×224	256×192	320×224	128×128

Note：TSE：turbo spin echo；SE：spin echo；TR：repetition time；TE：echo time；FOV：field of view

Table 2　EMVI classification and performance on MRI

MRI score	The morphological characteristics of MRI	MRI state
0	Rectal tumor invaded more than the intestinal wall, but the tumor was not nodular and had no adjacent vascular invasion	Negative
1	The smallest outer wall of the intestines	Negative
2	The tumor is close to the blood vessels, but there is no tumor signal in the blood vessels, and there is a normal vascular lumen	Negative
3	There are tumor signals in vascular lumen and vascular lumen dilation	Positive
4	There are tumor signals in the vascular lumen, irregular vessels in the large vessels, such as the upper, middle and inferior veins of the rectum	Positive

润。根据 2010 年 AJCC 的 TNM 分期系统[13]，确定术后肿瘤的病理学分期。

1.5　统计学处理

采用 SPSS 16.0 软件包进行统计学处理。统计 MRI 检出直肠癌 EMVI 的准确性、灵敏度、特异度、阳性预测值和阴性预测值。采用 Kappa 检验，比较 MRI 与病理结果的一致性，Kappa>0.75 表明一致性好；Kappa 0.40~0.75 表明一致性中等；Kappa<0.4 表明一致性差。$P<0.05$ 为差异有统计学意义。

2　结　果

2.1　直肠癌 MRI 的一般情况和手术、病理

全组患者按照 TME 原则行肿瘤切除手术，其中 9 例行经腹会阴联合切除术（Miles 手术方式），100 例行经腹（Dixon 手术方式）切除术。109 例均为直肠腺癌，其中 1 例高分化，105 例中分化，3 例低分化；溃疡型 54 例，隆起型 51 例，浸润型 4 例；T_1 期 15 例，T_2 期 31 例，T_3 期 61 例，T_4 期 2 例；N_0 期 37 例，N_1 期 72 例。

2.2　直肠癌 EMVI 的 MRI 评估

直肠周围正常的壁外血管的 MRI 特征是在 T2WI 为匍行性或曲折的线性结构（Figure 2）。病理学显示 EMVI 阳性的 18 例，EMVI 阴性 91 例，MRI 显示 EMVI 阳性 16 例（Figure 3），病理可见脉管浸润（Figure 4），EMVI 阴性 93 例（Figure 5），其中正确诊断 103 例，MRI 诊断 EMVI 总的准确性为 94.50%（103/109），灵敏度为 77.78%(14/18)，特异度为 97.80%(89/91)，阳性预测值 87.5%(14/16)，阴性预测值 95.70%

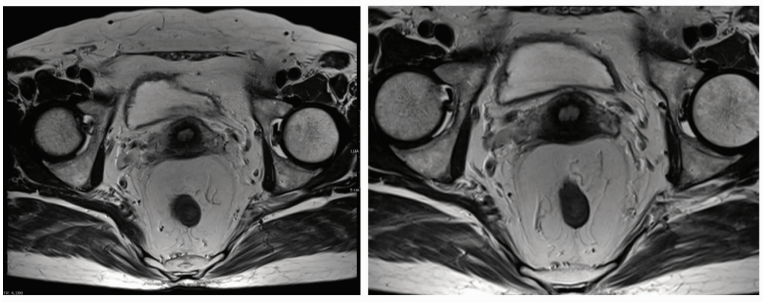

Axial T2WI　　Axial T2WI

Figure 2　Female，62 years old，showing normal external wall vessels in the mesorectal region

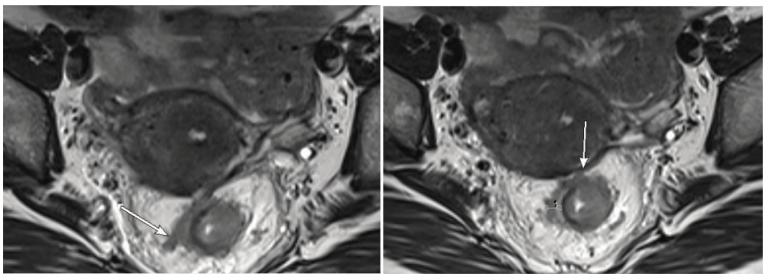

Axial T2WI　　Axial T2WI

Figure 3　Female，44 years old，EMVI positive，stage T_3

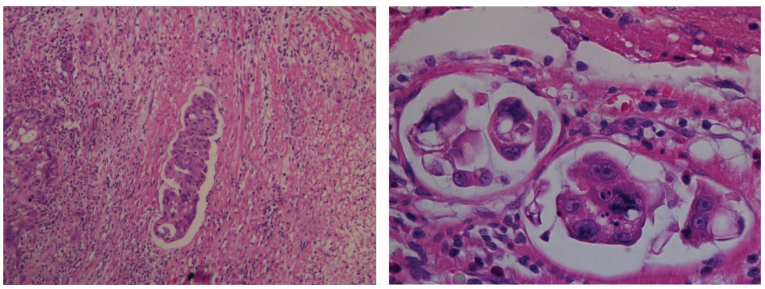

(HE×100)　　(HE×400)

Figure 4　Pathology lymphatic vascular invasion positive

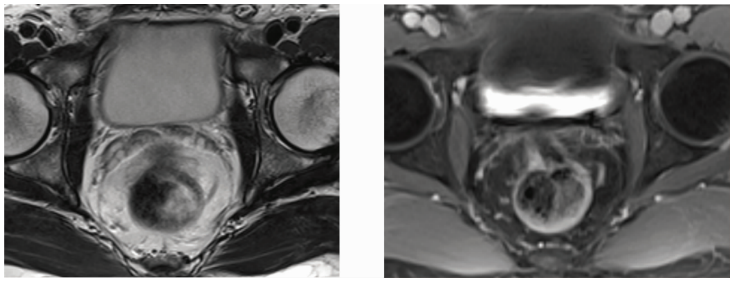

Axial T2WI　　Axial T1WI enhancement

Figure 5　Male,48 years old,tumor invasion circumferential margin,seminal vesicle no invasion,EMVI negative

(89/93)。过高诊断 2 例,过低诊断 4 例。MRI 与病理学对 EMVI 阳性的一致性检验,Kappa 值=0.791(P<0.001),显示两种诊断方法的一致性良好,说明 MRI 对 EMVI 与术后病理 EMVI 阳性的符合度良好。

根据术后病理结果,109 例患者中,MR 评估 EMVI 在 $T_{1\text{-}2}$ 期中 0 例,T_3 期 14 例(22.95%),T_4 期 2 例(100%),T 分期越高,MRI 诊断的 EMVI 阳性率越高。

3　讨　论

目前 MRI 已经被证明是能表明直肠癌 EMVI 存在的唯一成像方式[7,14]。但是,MR 评价 EMVI,合适的扫描序列非常重要。本研究中,轴位高分辨 T2WI 是诊断直肠癌 EMVI 的最重要序列。直肠 DWI,对于弥散加权成像 b 值,本研究取 b=0 和 800s/mm^2,参考多篇文献认为 b=800s/mm^2 是直肠癌 DWI 成像的合理 b 值[15-16],所以本研究采用 b=800 s/mm^2。此序列可以帮助评价肿瘤的 EMVI,但是必须结合高分辨率 T2WI。

EMVI 被定义为固有肌层外血管内存在肿瘤细胞[6,17]。组织病理学被视为肿瘤累及血管结构与平滑肌壁[18]。EMVI 严重程度与无瘤生存期(DFS)[4,19-20]相关,且 EMVI 是直肠癌局部和远处复发以及较差预后的独立危险因素[3-5,19,21-23]。根据定义,肿瘤侵犯深度可以提示潜在壁外血管侵犯时,肿瘤至少达 T_3 期,T_1 或 T_2 期肿瘤没有潜力对血管入侵。

直肠周围正常的壁外血管的 MRI 特征是在 T2WI 为匐行性或曲折的线性结构。EMVI 的 MRI 征象:(1)肿瘤的信号存在于血管结构内,(2)血管增宽,(3)肿瘤膨胀超出血管壁并破坏血管边界[6,17,24-26]。本研究中通过 MRI 对 EMVI 进行评估,将 EMVI 分为阳性和阴性两组,MRI 显示 EMVI 阳性 16 例,EMVI 阴性 93 例,其中正确诊断 103 例,MRI 诊断 EMVI 总的准确性为 94.50%(103/109),灵敏度为 77.78%(14/18),特异度为 97.80%(89/91)。MRI 与病理学对 EMVI 阳性的一致性检验,Kappa 值=0.791(P<0.001),显示两种诊断方法的一致性良好。其中过高诊断 2 例,过低诊断 4 例,分析其原因可能是因为部分血管内的肿瘤细胞较少,信号异常不明显,所以导致低估。高估的原因可能为部分血管和原发肿瘤接近,误认为血管腔扩张或边界不清。然而,MRI 观察 EMVI 的灵敏度和特异性报道不一,为 62%~100%和 88%~89%之间[27-28]。本研究的准确性有所提高,可能是因为本次应用高分辨率扫描方法,对 DWI、T2WI 进行了联合应用。

总之,高分辨 MRI 可很好的评估直肠癌 EMVI 的显示,MRI 诊断 EMVI 准确率高,与病理结果一致性好。MRI 能够为直肠癌的个体化治疗方案提供准确的影像学依据。

参考文献:

[1] Jemal A,Siegel R,Xu J,et al. Cancer statistics,2010[J]. CA Cancer J Clin,2010,60(5):277-300.

[2] Cellini F,Valentini V. Current perspectives on preoperative integrated treatments for locally advanced rectal cancer:a review of agreement and controversies [J]. Oncology (Williston Park),2012,26(8):730-741.

[3] Horn A,Dahl O,Morild I. Venous and neural invasion as predictors of recurrence in rectal adenocarcinoma [J]. Dis Colon Rectum,1991,34(9):798-804.

[4] Smith NJ,Barbachano Y,Norman AR,et al. Prognostic significance of magnetic resonance imaging-detected extramural vascular invasion in rectal cancer [J]. Br J Surg,2008,95(2):229-236.

[5] Betge J,Pollheimer MJ,Lindtner RA,et al. Intramural and extramural vascular invasion in colorectal cancer:prognostic significance and quality of pathology reporting[J]. Cancer,2012,118(3):628-638.

[6] Smith NJ,Shihab O,Arnaout A,et al. MRI for detection of extramural vascular invasion in rectal cancer [J]. AJR Am J Roentgenol,2008,191(5):1517-1522.

[7] Brown G,Radcliffe AG,Newcombe RG,et al. Preoperative assessment of prognostic factors in rectal cancer using high-resolution magnetic resonance imaging[J]. Br J Surg, 2003,90(3):355-364.

[8] Brown G,Richards CJ,Newcombe RG,et al. Rectal carcinoma:thin-section MR imaging for staging in 28 patients [J]. Radiology,1999,211(1):215-222.

[9] Brown G,Daniels IR,Richardson C,et al. Techniques and trouble-shooting in high spatial resolution thin slice MRI for rectal cancer[J]. Br J Radiol,2005,78(927):245-251.

[10] Zand KR,Reinhold C,Haider MA,et al. Artifacts and pitfalls in MR imaging of the pelvis[J]. J Magn Reson Imaging,2007,26(3):480-497.

[11] Nougaret S,Reinhold C,Mikhael HW,et al. The use of MR imaging in treatment planning for patients with rectal carcinoma:have you checked the"DISTANCE"?[J]. Radiology,2013,268(2):330-344.

[12] Langman G,Loughrey M,Shepherd N,et al. Association of Coloproctology of Great Britain & Ireland (ACPGBI): guidelines for the management of cancer of the colon,rectum and anus(2017) - pathology standards and datasets[J]. Colorectal Dis,2017,19(1):74-81.

[13] Edge SB,Byrd DR,Compton CC,et al. American Joint Committee on Cancer (AJCC) Cancer Staging Manual[M]. 7th ed. Chicago,IL:Springer,Inc,2010.143-164.

[14] Jhaveri KS,Hosseini-Nik H,Thipphavong S,et al. MRI detection of extramural venous invasion in rectal cancer: correlation with histopathology using elastin stain [J]. AJR Am J Roentgenol,2016,206(4):747-755.

[15] van Heeswijk MM,Lambregts DM,van Griethuysen JJ,et al. Automated and semiautomated segmentation of rectal tumor volumes on diffusion-weighted MRI:can it replace manual volumetry? [J]. Int J Radiat Oncol Biol Phys, 2016,94(4):824-831.

[16] Maas M,Lambregts DM,Nelemans PJ,et al. Assessment of clinical complete response after chemoradiation for rectal cancer with digital rectal examination,endoscopy,and MRI:selection for organ-saving treatment [J]. Ann Surg Oncol,2015,22(12):3873-3880.

[17] Chand M,Siddiqui MR,Swift I,et al. Systematic review of prognostic importance of extramural venous invasion in rectal cancer[J]. World J Gastroenterol,2016,22(4):1721-1726.

[18] Howlett CJ,Tweedie EJ,Driman DK. Use of an elastic stain to show venous invasion in colorectal carcinoma:a simple technique for detection of an important prognostic factor[J]. J Clin Pathol,2009,62(11):1021-1025.

[19] Chand M,Evans J,Swift RI,et al. The prognostic significance of postchemoradiotherapy high-resolution MRI and histopathology detected extramural venous invasion in rectal cancer[J]. Ann Surg,2015,261(3):473-479.

[20] Talbot IC,Ritchie S,Leighton MH,et al. The clinical significance of invasion of veins by rectal cancer [J]. Br J Surg,1980,67(6):439-442.

[21] Gunther K,Dworak O,Remke S,et al. Prediction of distant metastases after curative surgery for rectal cancer[J]. J Surg Res,2002,103(1):68-78.

[22] Rich T,Gunderson LL,Lew R,et al. Patterns of recurrence of rectal cancer after potentially curative surgery[J]. Cancer,1983,52(7):1317-1329.

[23] Chand M,Bhangu A,Wotherspoon A,et al. EMVI-positive stage Ⅱ rectal cancer has similar clinical outcomes as stage Ⅲ disease following preoperative chemoradiotherapy [J]. Ann Oncol,2014,25(4):858-863.

[24] Bhangu A,Fitzgerald JE,Slesser A,et al. Prognostic significance of extramural vascular invasion in T4 rectal cancer[J]. Colorectal Dis,2013,15(11):e665-6671.

[25] Chand M,Swift RI,Tekkis PP,et al. Extramural venous invasion is a potential imaging predictive biomarker of neoadjuvant treatment in rectal cancer [J]. Br J Cancer, 2014,110(1):19-25.

[26] Sohn B,Lim JS,Kim H,et al. MRI-detected extramural vascular invasion is an independent prognostic factor for synchronous metastasis in patients with rectal cancer[J]. Eur Radiol,2015,25(5):1347-1355.

[27] Koh DM,Smith NJ,Swift RI,et al. The relationship between MR demonstration of extramural venousinvasion and nodal disease in rectal cancer [J]. Clin Med Oncol, 2008,2:267-273.

[28] Bugg WG,Andreou AK,Biswas D,et al. The prognostic significance of MRI-detected extramural venous invasion in rectal carcinoma[J]. Clin Radiol,2014,69(6):619-623.